

Highland View Medical Center

1815 NW Overton St
Portland, Oregon 97209
Tel: 615-887-0233



DRAFT CORONARY INTERVENTION REPORT

Patient:	Newhart, Ivana	Patient Status:	REG
Date of Birth:	February 1, 1941	Date:	September 6, 2018
Gender:	F	Time:	9:13 AM
URN:	5186f_2	Location:	J.VEND ER
MRN:	f070966d_2	Room #:	Not Provided
Account Number:	a8b6453ad8_2	Admitting Physician:	Inmiami, Ahima

REPORT SUMMARY

Synopsis

INDICATION

77 year old female with unstable angina and abnormal nuclear medicine study. Here for diagnostic angiography and possible intervention.

PROCEDURES

Diagnostic Angiography	Bilateral Coronary Angiogram		
Left Heart Catheterization	Hemodynamic Details provided in the Report Details Section		
Left Ventriculography	EF 50% with Normal LV Size		
Angioplasty	Proximal Right Coronary Artery	2.25 x 20 mm Sprinter balloon	85 % (pre) to 40 % (post)
Stent	Proximal Right Coronary Artery	4 x 22 mm Resolute Integrity RX drug-eluting stent	40 % (pre) to 0 % (post)
	Proximal Left Circumflex Artery → Mid Left Circumflex Artery	2.25 x 8 mm Integrity RX bare metal stent	70 % (pre) to 0 % (post)

DIAGNOSTIC FINDINGS

DIAGNOSTIC CORONARY ANGIOGRAPHY (RIGHT DOMINANT)

LMCA	No significant findings.	
LAD	No significant findings.	
LCX	70% Stenosis	Proximal Left Circumflex Artery → Mid Left Circumflex Artery
RCA	85% Stenosis	Proximal Right Coronary Artery

LEFT VENTRICULOGRAPHY

LV Size	Normal
Ejection Fraction	50%

Post-Procedural Summary

IMPRESSIONS

High grade stenoses of both RCA and LCX, treated successfully with stent deployments. Normal LV function.

ADVERSE EVENTS

No known adverse events

RECOMMENDATIONS

81 mg of ASA per day

Routine post-PCI care

Refer for cardiac rehab

STRUCTURED DICTATION

CASE DICTATION

Upon arrival to the cath lab, the patient was prepped and draped in the usual sterile manner. Local anesthesia was utilized. I was personally responsible for the intra-procedural administration of moderate sedation and affirm the use of an independent trained observer. The face-to-face time was 34 minutes. Realtime ultrasound guidance was used to achieve percutaneous vascular access of the mid right common femoral artery. The vessel was patent, and an image was obtained and placed in the permanent medical record. A 7 French Brite Tip sheath was used for procedure(s) performed via this access.

A 6 French JR3.5 catheter and a 6 French JL3.5 catheter were then advanced into the origin of the left and right coronary arteries. Contrast was injected, and a diagnostic bilateral coronary angiogram was performed. (2) findings were noted as follows: an 85% atherosclerotic stenosis in the proximal right coronary artery and a 70% atherosclerotic stenosis from the proximal to the mid left circumflex artery [*No evidence of post-treatment embolic complication.*].

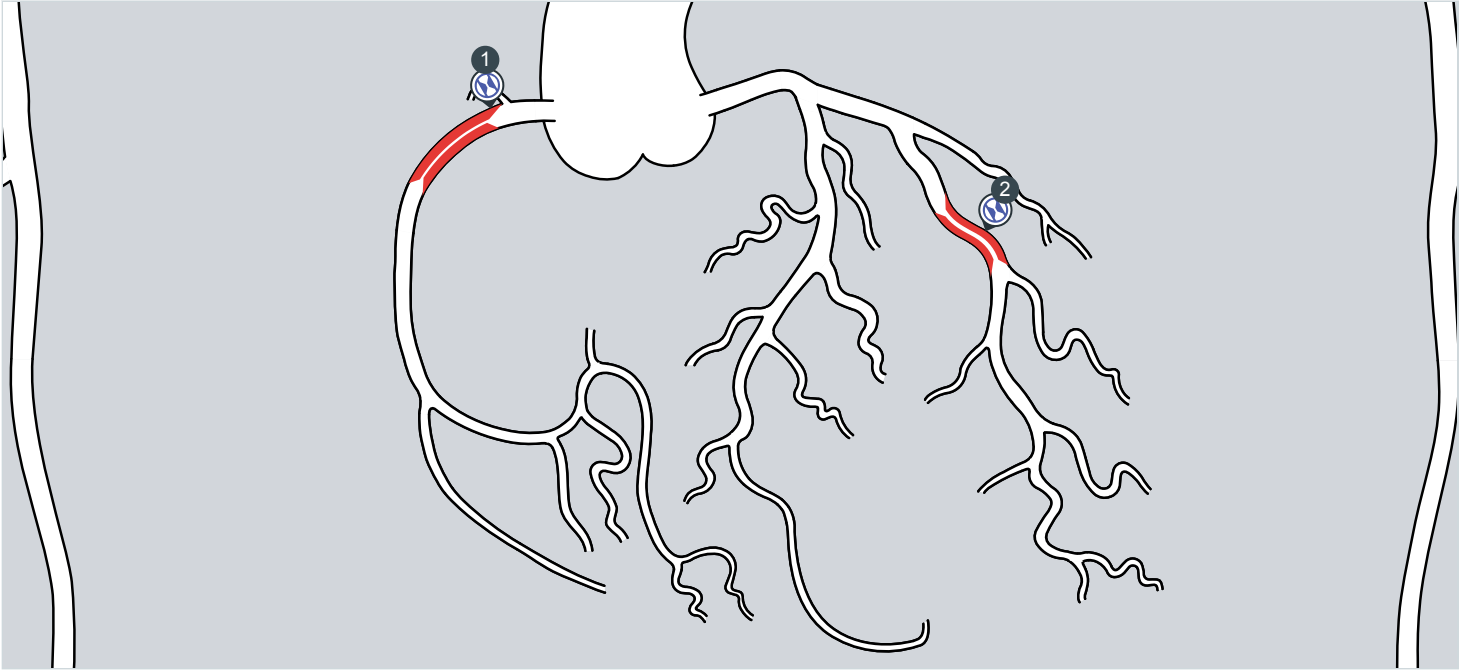
A 2.25 x 20 mm Sprinter balloon was inserted and advanced across the 85% stenosis in the proximal right coronary artery. An angioplasty was performed, resulting in a post-intervention stenosis percentage of 40%. [*After angioplasty there appeared to be a limited dissection which resolved itself upon stent placement.*] A 4 x 22 mm Resolute Integrity RX drug-eluting stent was then inserted and advanced to the previously treated stenosis and deployed, resulting in a post-intervention stenosis percentage of 0%. An 8 French JL4 CRV guide catheter was inserted and engaged the origin of the left main coronary artery, and a 0.014 x 335cm ViperWire guidewire was advanced across the 70% stenosis from the proximal to the mid left circumflex artery. A 2.25 x 8 mm Integrity RX bare metal stent was deployed, resulting in a post-intervention stenosis percentage of 0%.

A 5 French Impulse Pigtail catheter was inserted and advanced into the left ventricle, and left heart hemodynamics were obtained (please see procedure details and/or hemodynamic report for complete measurements). The catheter remained in the left ventricle, contrast was injected and left ventriculography was performed. LV size was normal, and the ejection fraction was 50%. There were no aortic valve abnormalities noted. There were no mitral valve abnormalities noted.

All devices were removed from the access site in the mid right common femoral artery, and the access was closed with a 6 French Angio-Seal VIP closure device.

GRAPHICAL REPORT

Findings Summary: Coronaries

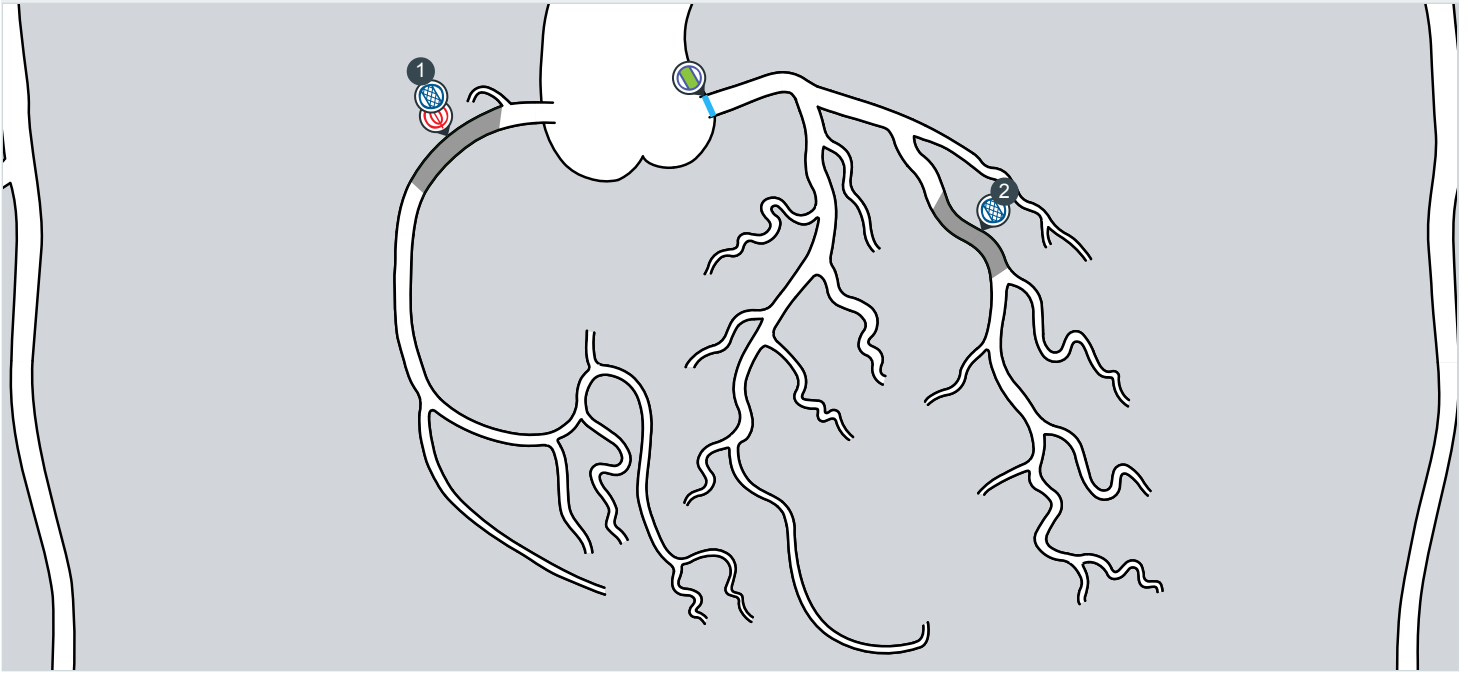


Diagnostic Bilateral Coronary Angiogram: Origin of the Right and Left Main Coronary Arteries


1 Stenosis: Proximal Right Coronary Artery
Percentage **85%**


2 Stenosis: Proximal Left Circumflex Artery
→ Mid Left Circumflex Artery
Percentage **70%**

Procedures Summary: Coronaries




1 Stenosis: Proximal Right Coronary Artery

 **Angioplasty**
85% → 40%

 **Stent**
40% → 0%

2 Stenosis: Proximal Left Circumflex Artery → Mid Left Circumflex Artery

 **Stent**
70% → 0%

REPORT DETAILS

Vascular Access

ACCESS SITE # 1 - MID RIGHT COMMON FEMORAL ARTERY

Access Type:	Percutaneous
Sheath(s) Used:	7 French Brite Tip sheath
Closure Device(s) Used:	6 French Angio-Seal VIP closure device
Disposition:	Used closure device

Diagnostics

HEART CATH DETAILS

LEFT HEART CATH

Catheter(s) Used: 5 French Impulse Pigtail catheter (used 2 times)
GUIDEWIRE VASC 335CM .014IN (used 5 times)

Pressure Samples (mmHg):

LV	Systolic 100 , End Diastolic 22
	Systolic 95 , End Diastolic 19
Ao	Systolic 95 , Diastolic 73 , Mean 83
	Systolic 93 , Diastolic 68 , Mean 79

STRUCTURAL HEART DIAGNOSTICS

LEFT VENTRICULOGRAPHY

Diagnostic Catheter(s)	Guide Wire(s)	Additional Information
5 French Impulse Pigtail catheter (used 2 times)	GUIDEWIRE VASC 335CM .014IN (used 5 times)	LV Size: Normal Aortic Valve Normal Mitral Valve Normal Ejection Fraction: 50%

FINDINGS: No significant findings.

DIAGNOSTIC ANGIOGRAPHY

BILATERAL CORONARY ANGIOGRAM

Catheter Tip Location	Catheter(s)	Guide Wire(s)	Dominance
Origin of the Right and Left Main Coronary Arteries	6 French JR3.5 catheter 6 French JL3.5 catheter	GUIDEWIRE VASC 335CM .014IN (used 5 times)	Right Dominant

STENOSIS

Location	Percentage	Length	TIMI	Lesion Type	Appearance	Calcification
Proximal Right Coronary Artery	85%	16mm	TIMI3	Type A	Concentric	Mild
Proximal Left Circumflex Artery → Mid Left Circumflex Artery ¹	70%	10mm	TIMI3	Type A	Eccentric	None

¹ No evidence of post-treatment embolic complication.

Interventions

CORONARY INTERVENTIONS

STENOSIS: PROXIMAL RIGHT CORONARY ARTERY

Angioplasty

Balloon: 2.25 x 20 mm Sprinter balloon
Deployment Pressure: 8 ATM, Inflation Time: 30s

Stenosis Percentage: 85% Pre-Intervention 40% Post-Intervention

TIMI Flow: Pre-Intervention: TIMI3
Post-Intervention: TIMI3

Notes: After angioplasty there appeared to be a limited dissection which resolved itself upon stent placement.

Stent

Stent Device: 4 x 22 mm Resolute Integrity RX drug-eluting stent
Deployment Pressure: 8 ATM

Stenosis Percentage: 40% Pre-Intervention 0% Post-Intervention

TIMI Flow: Pre-Intervention: TIMI3
Post-Intervention: TIMI3

Guide Catheter(s): CATHETER SUPP 150CM TRLBLZR

Guide Wire(s): GUIDEWIRE VASC 335CM .014IN

STENOSIS: PROXIMAL LEFT CIRCUMFLEX ARTERY → MID LEFT CIRCUMFLEX ARTERY

Stent

Stent Device: 2.25 x 8 mm Integrity RX bare metal stent
Deployment Pressure: 8 ATM

Stenosis Percentage: 70% Pre-Intervention 0% Post-Intervention

TIMI Flow: Pre-Intervention: TIMI3
Post-Intervention: TIMI3

Guide Catheter(s): 8 French JL4 CRV guide catheter

Guide Wire(s): GUIDEWIRE VASC 335CM .014IN

Case Details

FLUOROSCOPY

AMOUNT	TIME
12356 gy	4.5 min

CONTRAST

CONTRAST NAME	TOTAL OPENED	TOTAL USED
Isovue-370	175 mL	100 mL

LOGISTICS

PATIENT ARRIVAL	CASE START	CASE COMPLETE	PATIENT DISCHARGE
3:26 PM	3:53 PM	4:17 PM	4:37 PM

ANESTHESIA

Type of Anesthesia Used	Local Anesthesia	See nursing log for details of medications administered and patient evaluations.
--------------------------------	------------------	--

Type of Sedation Used	Moderate Conscious Sedation	See nursing log for details of medications administered and patient evaluations.
------------------------------	-----------------------------	--

MS services provided by physician performing the procedure	Yes
---	-----

Face to Face Time	34 minutes
--------------------------	------------

Trained Independent Observer Present throughout moderate sedation	Yes
--	-----

MEDICATION TOTALS

MEDICATION	DOSE	ROUTE	TIME	REASON
VERSED	2 mg		3:39 PM	As per physicians verbal order
FENTANYL	50 mcg		3:39 PM	As per physicians verbal order
IV SOLUTIONS	0 mL (IV)		3:40 PM	As per physicians verbal order
FENTANYL	100 mcg		3:47 PM	As per physicians verbal order
VERSED	1 mg		3:48 PM	As per physicians verbal order
VERSED	1 mg		3:53 PM	As per physicians verbal order
FENTANYL	50 mcg		3:53 PM	As per physicians verbal order
OXYGEN	5 l/min		3:57 PM	As per physicians verbal order

Devices

Sheaths:	7 French Brite Tip sheath 8 French 23 cm Avantisheath
Catheters:	5 French Impulse Pigtail catheter (used in 2 procedures) 6 French JR3.5 catheter 6 French JL3.5 catheter 8 French JL4 CRV guide catheter 8 French JR4 CRV guide catheter CATHETER SUPP 150CM TRLBLZR
Guide Wires:	GUIDEWIRE VASC 335CM .014IN (used in 5 procedures) GUIDEWIRE VASC 335CM .014IN
Procedural Devices:	6 French Export aspiration catheter 4 French Spiroflex AngioJet catheter 1.50 mm Rotablator device 1.7 mm Turbo Elite laser catheter 4 x 22 mm Resolute Integrity RX drug-eluting stent 5 French IVUS catheter Filterwire embolic protection device 2.25 x 20 mm Sprinter balloon 3.5 x 25 mm Sprinter balloon 2.25 x 8 mm Integrity RX bare metal stent Impella CP percutaneous LVAD
Closure Devices:	6 French Angio-Seal VIP closure device
